



THE COLLEGE OF
OPTOMETRISTS

Stage Two

Overarching case scenario 11

AGE AND GENDER Female aged 88 years, Caucasian.

OCCUPATION AND HOBBIES Retired. Non-driver. Has had to stop most hobbies.

PRESENTING SYMPTOMS AND HISTORY Finding it hard to see hand signs. Would like a magnifier to be able to read a few words e.g. to see who a letter is from or read back a reminder note. Needs bright light to see, but is dazzled outdoors on a sunny day - sun glasses of little use. A guide communicator visits for 3 hours everyday and helps with correspondence and shopping. Meals on wheels daily and she has home help to clean and shop etc. Diagnosed as having marked bilateral cataracts . Last HES appointment 3 months ago. Ophthalmologist will not operate because not able to lip read during local anaesthetic and general anaesthetic inadvisable due to heart problems.

GENERAL HEALTH AND MEDICATION Very deaf since birth and has always used sign language. Has had three mini-strokes in the last 3 years and suffers from angina, high blood pressure and arthritis. Takes 10 tablets per day including Warfarin (other names not known and no record brought).

PRESENT Rx, CENTRATION AND ACUITIES CR39 R22 Bifocals OC64

Distance RE: +3.50/-1.00 x 120 **6/76**
LE: +3.25/-0.50 x 90 **6/95**
Near Add +4.50D **RE: N36 @ 22cm LE: <N60**

PD/NCD 64/61 at 40cm

VISION Distance RE: 6/150 LE: 6/150 **PINHOLE VISION** did not understand

REFRACTION

RE: +3.50/-1.00 x 90 (+/- 3.00 worse)

LE: +3.25/-0.50 x 90 (+/- 3.00 worse) Add +4.50

VA Distance RE: 6/76 LE: 6/95

Near RE: N36 @ 22cm LE: <N60

ACCOMMODATION Not done

BINOCULAR STATUS Not done

MOTILITY Not done

CONVERGENCE Not done

PUPIL REACTIONS direct and consensual reflexes present but minimal. No RAPD

FUNDUS EXAMINATION very poor view see attached

FIELDS Automated perimetry not possible. Confrontation fields slightly constricted both eyes.

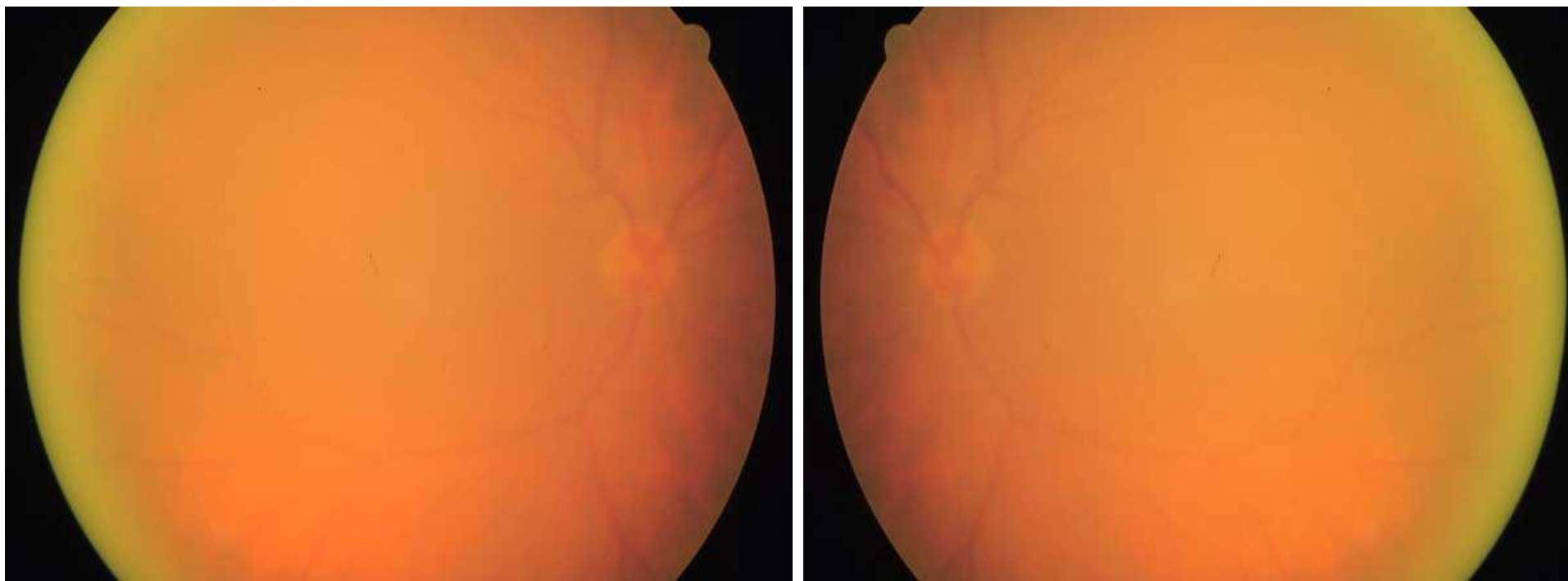
IOP RE: 14mmHg LE: 14mmHg Goldmann at 10.50am

EXTERNAL EYE EXAMINATION see attached

COLOUR VISION not done

CONTRAST SENSITIVITY Pelli-Robson Binocular log contrast sensitivity 0.50

Fundus Image



External Eye LE (RE Similar)

